

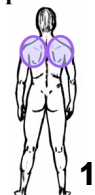Muscles – List by Group

Muscles are placed in groups based on the bones and joints they *move* as they contract.

----- (Chapter 4) -----

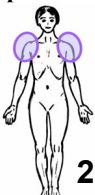Group 1 – Scapula / Clavicle

Trapezius
Levator scapula
Rhomboid major & minor
Serratus anterior
Pectoralis minor
Subclavius



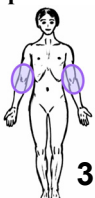
Group 2 – Shoulder Joint

Deltoid
Supraspinatus
Infraspinatus
Teres minor
Subscapularis
Pectoralis major
Coracobrachialis
Latissimus dorsi
Teres major



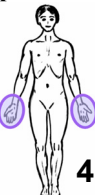Group 3 – Elbow, Forearm

Biceps brachii
Brachialis
Brachioradialis
Pronator teres
Pronator quadratus
Triceps brachii
Anconeus
Supinator



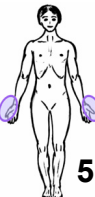Group 4 – Wrist, Hand, Fingers

Flexor carpi radialis
Palmaris longus
Flexor carpi ulnaris
Flexor digitorum superficialis
Flexor digitorum profundus
Extensor carpi radialis longus
Extensor carpi radialis brevis
Extensor carpi ulnaris
Extensor digitorum
Extensor indicis



Group 5 – Thumb

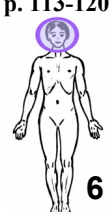Flexor pollicis longus
Flexor pollicis brevis
Opponens pollicis
Adductor pollicis
Abductor pollicis longus
Abductor pollicis brevis
Extensor pollicis longus
Extensor pollicis brevis
Intrinsic muscles of the hand



----- (Chapter 5) -----

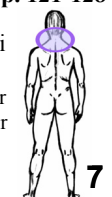
Group 6 – Face, Jaw

Masseter
Temporalis
Lateral pterygoid
Medial pterygoid
Occipitofrontalis
Platysma
Suprahyoids Group
Geniohyoid, Mylohyoid,
Stylohyoid, Digastric
Infrahyoids Group
Sternohyoid, Sternothyroid,
Omohyoid, Thyrohyoid
Muscles of facial expression



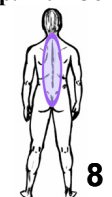Group 7 – Neck, Head

Sternocleidomastoid
Scalenes group
Longus capitis & longus colli
Suboccipital group
Rectus Capitis Posterior Major
Rectus Capitis Posterior Minor
Oblique Capitis Superior
Oblique Capitis Inferior
Splenius capitis
Splenius cervicis
Semispinalis capitis
Levator scapula*
Trapezius, upper fibers*
*(revisited for reversed O/I actions)



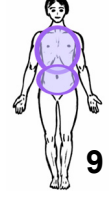
Group 8 – Spine

Spinalis
Longissimus
Iliocostalis
Semispinalis
Multifidus
Rotatores
Quadratus lumborum
Interspinales & Intertransversarii



Group 9 – Thorax, Abdomen, Breathing

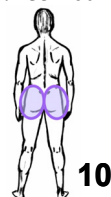Rectus abdominis
External oblique
Internal oblique
Transverse abdominis
Diaphragm
External intercostals
Internal intercostals
Serratus posterior superior
Serratus posterior inferior
Levator costae



----- (Chapter 6) -----

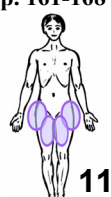
Group 10 – Hip Joint (Part 1)

Gluteus maximus
Gluteus medius
Gluteus minimus
Piriformis (1st lateral rotator)
The other 5 lateral rotators
Gemellus Superior
Obturator Internus
Gemellus Inferior
Obturator Externus
Quadratus Femoris
Iliopsoas
(Iliacus & Psoas major)



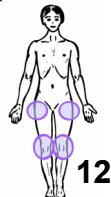
Group 11 – Hip Joint (Part 2)

Sartorius
Tensor fascia latae
Pectineus
Adductor brevis
Adductor longus
Adductor magnus
Gracilis



Group 12 – Knee (& Hip Joint, Part 3)

Rectus femoris
Vastus lateralis
Vastus intermedius
Vastus medialis
Biceps femoris
Semitendinosus
Semimembranosus
Popliteus



Group 13 – Ankle, Foot, Toes

Gastrocnemius
Plantaris
Soleus
Tibialis posterior
Flexor digitorum longus
Flexor hallucis longus
Peroneus longus
Peroneus brevis
Tibialis anterior
Extensor digitorum longus
Extensor hallucis longus
Intrinsic muscles of the foot

