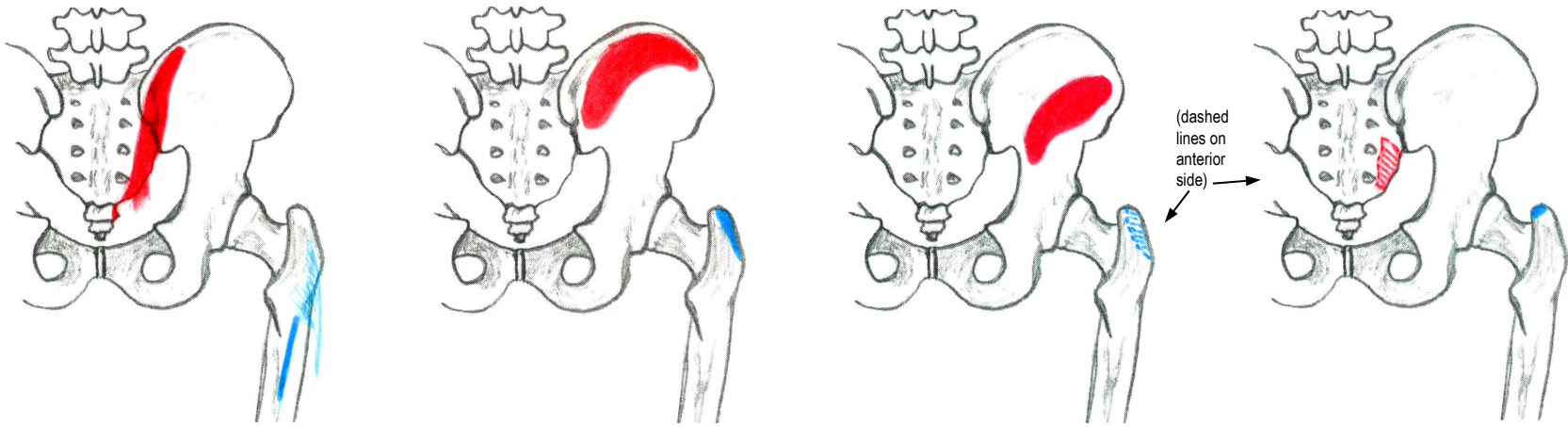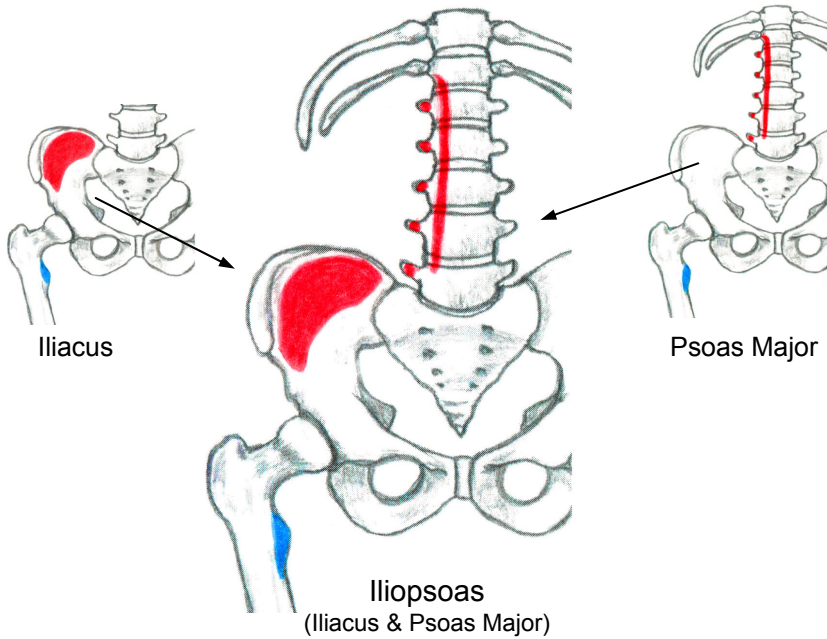


Gluteus Maximus

Gluteus Medius

Gluteus Minimus

Piriformis

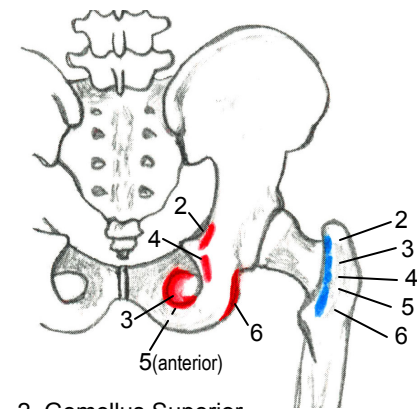


Iliacus

Psoas Major

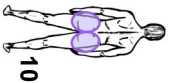
Iliopsoas
(Iliacus & Psoas Major)

The Deep Six Lateral Rotators { - Piriformis (see above)
- The other 5 (see 2.-6. below)



- 2. Gemellus Superior
- 3. Obturator Internus
- 4. Gemellus Inferior
- 5. Obturator Externus
- 6. Quadratus Femoris

Hip Joint (Part 1)



Origins are red
Insertions are blue

Lift page to see muscle pictures

Figure 10 (A) - Hip Joint (Part 1) - Muscle Attachments