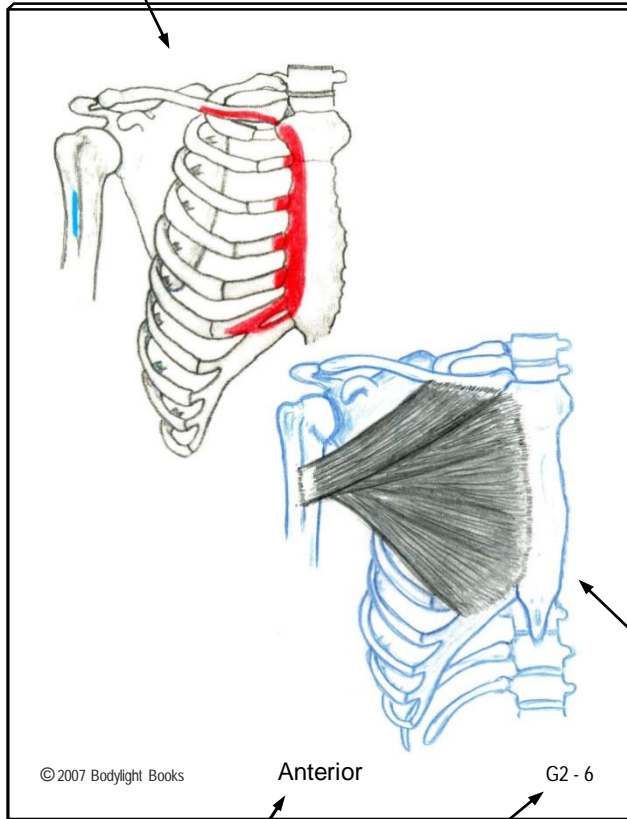


Illustration of muscle's attachments to the bones

Origin: Shown in **Red**
Insertion: Shown in **Blue**
Action: Visualize the **blue** being pulled toward the **red**



© 2007 Bodylight Books

Anterior

G2 - 6

Aspect of the body you are viewing

Muscle Identifier*

* Muscle identifiers include a hierarchical numbering system that matches the muscle groups in the textbook.

MusclePlus+ Flashcards

- Full color double-illustration flashcards provide a unique way to study the muscles of the body
- 140 cards covering 180 muscles
- Includes illustrated booklet with bones, actions, muscle lists by group, and study tips
- Companion flashcards that go with the textbook:

Mastering Muscles & Movement

A Brain-Friendly System for Learning Musculoskeletal Anatomy and Basic Kinesiology

www.bodylightbooks.com

Muscle Illustration (fibers show direction(s) of pull)

(Cards are shown actual size - 3¼" x 4¼")

Pectoralis Major

Origin:

Clavicular head: Medial half of the clavicle

Sternocostal part: Sternum & cartilages of ribs 1-6

Insertion: Intertubercular groove of the humerus (lateral lip)

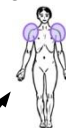Action:

All fibers: Adduction and medial rotation of the humerus at the shoulder joint

Upper fibers: Flexion and horizontal adduction of the humerus

Lower fibers: Extension of the humerus (from a flexed position), and depression of the shoulder girdle

Nerve: Lateral Pectoral N. (C5-C7) & Medial Pectoral N. (C8,T1)



MMM, p. 80

G2 - 6

Page reference in the book "Mastering Muscles & Movement"

Icon indicating the joint(s) moved by the muscle

Muscle Identifier*

MusclePlus+ Flash Cards

Upper Extremity

Movement of the Scapula/Clavicle

- G1-1 Trapezius
- G1-2 Levator Scapula
- G1-3 Rhomboid Major and Minor
- G1-4 Serratus Anterior
- G1-5 Pectoralis Minor
- G1-6 Subclavius

Movement of the Shoulder Joint

- G2-1 Deltoid
- G2-2 Supraspinatus
- G2-3 Infraspinatus
- G2-4 Teres Minor
- G2-5 Subscapularis
- G2-6 Pectoralis Major
- G2-7 Coracobrachialis
- G2-8 Latissimus Dorsi
- G2-9 Teres Major

Movement of the Elbow & Forearm

- G3-1 Biceps Brachii
- G3-2 Brachialis
- G3-3 Brachioradialis
- G3-4 Pronator Teres
- G3-5 Pronator Quadratus
- G3-6 Triceps Brachii
- G3-7 Anconeus
- G3-8 Supinator

Movement of Wrist, Hand, & Fingers

- G4-1 Flexor Carpi Radialis
- G4-2 Palmaris Longus
- G4-3 Flexor Carpi Ulnaris
- G4-4 Flexor Digitorum Superficialis
- G4-5 Flexor Digitorum Profundus
- G4-6 Extensor Carpi Radialis Longus
- G4-7 Extensor Carpi Radialis Brevis
- G4-8 Extensor Carpi Ulnaris
- G4-9 Extensor Digitorum
- G4-10 Extensor Indicis
- G4-11 Dorsal Interossei (4) *
- G4-12 Palmar Interossei (3) *
- G4-13 Lumbricales (4) *
- G4-14: Mms of the Hypothenar Eminence (3)
 - A. Abductor Digiti Minimi *
 - B. Flexor Digiti Minimi Brevis *
 - C. Opponens Digiti Minimi *

* (intrinsic muscles of the hand)

© 2010 Bodylight Books

Movement of the Thumb

- G5-1 Flexor Pollicis Longus
- G5-2 Flexor Pollicis Brevis *
- G5-3 Opponens Pollicis *
- G5-4 Adductor Pollicis *
- G5-5 Abductor Pollicis Longus
- G5-6 Abductor Pollicis Brevis *
- G5-7 Extensor Pollicis Longus
- G5-8 Extensor Pollicis Brevis

*(intrinsic muscles of the hand)

Axial Skeleton

Movement of the Face and Jaw

- G6-1 Masseter
- G6-2 Temporalis
- G6-3 Lateral Pterygoid
- G6-4 Medial Pterygoid
- G6-5 Occipitofrontalis
- G6-6 Platysma
- G6-7 Suprahyoids Group
 - A. Geniohyoid
 - B. Mylohyoid
 - C. Stylohyoid
 - D. Digastric
- G6-8 Infrahyoids Group
 - A. Sternohyoid
 - B. Sternothyroid
 - C. Omohyoid
 - D. Thyrohyoid
- G6-9 Muscles of Facial Expression -
Buccinator, Orbicularis Oris, Orbicularis Oculi,
Zygomaticus Maj. & Min., etc. (14 mms)

Movement of the Neck and Head

- G7-1 Sternocleidomastoid
- G7-2 Scalenes (Anterior, Middle & Posterior)
- G7-2 (A) Anterior Scalene
- G7-2 (B) Middle Scalene
- G7-2 (C) Posterior Scalene
- G7-3,4 : 3. Longus Capitis 4. Longus Colli
- G7-5 Suboccipital Group
 - A. Rectus Capitis Posterior Major
 - B. Rectus Capitis Posterior Minor
 - C. Oblique Capitis Superior
 - D. Oblique Capitis Inferior
- G7-6 Splenius Capitis
- G7-7 Splenius Cervicis
- G7-8 Semispinalis Capitis
- G7-9 Levator Scapula (reversed O/I action)
- G7-10 Trapezius, upper fibers (reversed O/I action)
- G7-11 Deep Anterior Neck Muscles (Prevertebral)

Axial Skeleton (continued)

Movement of the Spine

- G8-1 Spinalis (Cervicis and Thoracis)
- G8-2 Longissimus (Capitis, Cervicis and Thoracis)
- G8-3 Iliocostalis (Cervicis, Thoracis and Lumborum)
- G8-4 Semispinalis (Capitis, Cervicis and Thoracis)
- G8-5 Multifidus
- G8-6 Rotatores (Longus and Brevis)
- G8-7 Quadratus Lumborum
- G8-8 A. Interspinalis, B. Intertransversarii

Bonus Cards:

- G8-1 (A,B): Spinalis (separated by spinal section)
- G8-2 (A,B,C): Longissimus (sep. by spinal section)
- G8-3 (A,B,C): Iliocostalis (sep. by spinal section)
- G8-4 (A,B,C): Semispinalis (sep. by spinal section)
- G8-6 (A,B): Rotatores (separate Longus & Brevis)
- G8-1,2,3: Erector Spinae Group
- G8-4,5,6: Comparison of Transversospinal Muscles

Movement of the Thorax, Abdomen, Breathing

- G9-1 Rectus Abdominis
- G9-2 External Oblique
- G9-3 Internal Oblique
- G9-4 Transverse Abdominis
- G9-5 Diaphragm
- G9-6 External Intercostals
- G9-7 Internal Intercostals
- G9-8 Serratus Posterior Superior
- G9-9 Serratus Posterior Inferior
- G9-10 Levator Costae
- G9-X Muscles Surrounding the Abdominal Cavity

Lower Extremity

Movement of the Hip Joint (part 1)

- G10-1 Gluteus Maximus
- G10-2 Gluteus Medius
- G10-3 Gluteus Minimus
- G10-4 Piriformis (1st of the Deep 6 lat. rotators)
- G10-5 The "Deep Six" Lateral Rotators
 - 1. Piriformis
 - 2. Gemellus Superior
 - 3. Obturator Internus
 - 4. Gemellus Inferior
 - 5. Obturator Externus
 - 6. Quadratus Femoris
- G10-6 Iliacus
- G10-7 Psoas Major
- G10-6+7 Iliopsoas (Iliacus + Psoas Major)

Movement of the Hip Joint (part 2)

- G11-1 Sartorius
- G11-2 Tensor Fasciae Latae
- G11-3 Pectineus
- G11-4 Adductor Brevis
- G11-5 Adductor Longus
- G11-6 Adductor Magnus
- G11-7 Gracilis
- G11-3,4,5,6,7 Adductor Group Attachments
- G11-X: Muscles of the Thigh (Anterior View)

Movement of the Knee (& Hip Joint, part 3)

- G12-1 Rectus Femoris
- G12-2 Vastus Lateralis
- G12-3 Vastus Intermedius
- G12-4 Vastus Medialis
- G12-5 Biceps Femoris
- G12-6 Semitendinosus
- G12-7 Semimembranosus
- G12-8 Popliteus

Movement of the Ankle, Foot & Toes

- G13-1 Gastrocnemius
- G13-2 Plantaris
- G13-3 Soleus
- G13-4 Tibialis Posterior
- G13-5 Flexor Digitorum Longus
- G13-6 Flexor Hallucis Longus
- G13-7 Peroneus Brevis
- G13-8 Peroneus Longus
- G13-9 Tibialis Anterior
- G13-10 Extensor Digitorum Longus
- G13-11 Extensor Hallucis Longus
- G13-12 Peroneus Tertius

Intrinsic Muscles of the Foot

Four Plantar Layers:

- G13-13: 1st Layer:
 - A. Abductor Digiti Minimi,
 - B. Flexor Digitorum Brevis,
 - C. Abductor Hallucis
 - G13-14: 2nd Layer:
 - A. Lumbrical Muscles (4),
 - B. Quadratus Plantae
 - G13-15: 3rd Layer:
 - A. Flexor Digiti Minimi,
 - B. Adductor Hallucis,
 - C. Flexor Hallucis Brevis
 - G13-16: 4th Layer:
 - A. Plantar Interossei (3),
- Dorsal Aspect:
- G13-17: 1st Layer:
 - A. Extensor Digitorum Brevis
 - B. Extensor Hallucis Brevis
 - G13-18: 2nd Layer:
 - A. Dorsal Interossei (4)

Bonus Cards: Leg Muscles by Compartment

- G13-X Leg Cross-section (showing compartments)
- G13-AC Leg Muscles- Anterior Compartment
- G13-LC Leg Muscles- Lateral Compartment
- G13-SPC Leg Muscles- Superf. Post. Compartment
- G13-DPC Leg Muscles- Deep Post. Compartment

(140 cards covering 180 muscles)